

Invisible Facial Flushing in COVID-19 Patient Rapidly Detected by Smartphone Application: Subclinical Discovery with a Novel Method

MANOTE ARPORNSUWAN, M.D.

manote_arpornsuwan@yahoo.com

Buriram Hospital, Buriram 31000,
Thailand

ORCID: 0000-0001-9689-4157

MATINUN ARPORNSUWAN, M.D.

manutdpong@gmail.com

Medical Physician, Bangkok 10400,
Thailand

ORCID : 0000-0002-4642-9406

ABSTRACT

No studies of COVID-19 patients mentioned that facial flushing was a clinical feature that could be found. The invisible facial flushing in COVID-19 patient, unrecognized clinical sign with the naked eye could be detected by the smartphone application and probably was the most common clinical features of Coronavirus disease 2019 as seen in dengue infection and influenza. We discovered the innovative method which can detect invisible facial flushing in dengue infection and influenza by using image enhancement with decorrelation combined image segmentation with K-means clustering. We expect to be able to apply to the COVID-19 patient too, because the clinical signs and symptoms, including the immunopathogenesis of dengue infection and influenza are similar to COVID-19. This is the first case of the COVID-19 patient with the appearance of invisible facial flushing detected by the smartphone application. The innovative application may be useful as a rapid screening tool for diagnosis of COVID-19 patients in the future. This novel screening tool for diagnosis of COVID-19 patients will help all medical service providers the effective screening tool for the recognition and early diagnosis before performing CT scans and real-time RT PCR (rRT-PCR) assays, especially in some health care facilities where could not be performed due to lack of laboratory support. Furthermore, application in active case finding for COVID-19, the key actions to stop transmission is challenging in countries with community transmission.

Keywords: Facial Flushing, COVID-19, Image Enhancement, Image Segmentation, Smartphone Application, Rock Art Enhancer App

Introduction

Coronavirus: COVID-19 is now officially a pandemic. The COVID-19 viral disease that has swept into at least 185 countries and infected more than 2,000,000 people worldwide, including killing more than 130,000 people¹. Early diagnosis of coronavirus disease 2019 (COVID-19) is crucial for disease treatment and control. In the absence of specific therapeutic drugs or vaccines for COVID-19, it is essential to detect the disease at an early stage and immediately isolate an infected patient from the healthy population. Clinical characteristics of COVID-19 in China found that fever was present in 43.8% of the patients on admission but developed in 88.7% during hospitalization. Of 975 CT scans that were performed at the time of admission, 86.2% revealed abnormal results.²

In a study of more than 1,000 patients published in the journal *Radiology*, chest CT scans outperformed lab testing in the diagnosis of 2019 novel coronavirus disease (COVID-19).³ The researchers concluded that CT scans should be used as the primary screening tool for COVID-19. CT imaging may offer better sensitivity than RT-PCR testing for coronavirus. The research found that the sensitivity of CT scans for COVID-19 infection was 98 percent compared to RT-PCR testing sensitivity of 71 percent. CT scans provide best diagnosis for novel Coronavirus (COVID-19) and CT scans can detect coronavirus in patients before RT-PCR lab testing. Therefore, compared to RT-PCR, chest CT imaging may be a more reliable, practical and rapid method to diagnose and assess COVID-19, especially in the epidemic area.

All studies about the clinical characteristics of COVID-19, no studies of COVID-19 patients mention that facial flushing is a clinical feature that can be found.^{2, 4} Generally, if we look for facial flushing in COVID-19 patients with the naked eye, it will be difficult to see easily, as the skin color on the faces of different patients is obscured for us to be clearly observed. It was dependent on multiple factors such as races, skin color, skin pigmentation, anemia status, and observer bias. We discovered the innovative method which can detect invisible facial flushing in dengue infection and influenza by using image enhancement with decorrelation combined image segmentation with K-means clustering.⁶ Next we could apply the enhanced single face photo as a novel screening tool for diagnosis of dengue infection and influenza.⁷ The sensitivity of three steps modified Manote and Matinun technique for all tests in dengue, influenza patients was 96.8%. We expect to be able to apply to the COVID-19 patient too, because the clinical signs

and symptoms, including the immunopathogenesis of dengue infection and influenza are similar to COVID-19.^{8,9}

The immunopathogenesis of dengue infection and influenza is the appearance of hypercytokinemia ("cytokine storm") which is characterized by the extreme (exaggerated) production and secretion of large numbers and excessive levels of pro-inflammatory cytokines as well as emerging pathogenic viruses such as Ebola and Middle Eastern Respiratory Syndrome coronavirus (MERS-CoV).¹⁰ Huang, et al. describe the characteristics and clinical course of hospitalized patients infected with the 2019 novel coronavirus who did, or did not, require treatment in the intensive care unit (ICU). Those that were admitted to the ICU, particularly those with severe disease, exhibited significantly higher levels of inflammatory cytokines compared to those that did not.⁴

The first most common symptom and sign in dengue infection, influenza and COVID-19 was fever. The known endogenous pyrogens were IL-1 α and -1 β , TNF- α and - β , IL-6 and IFN- α which these proinflammatory cytokines had been proposed as mediators of fever.¹¹ Likewise, the appearance of facial flushing in dengue infection and influenza both visible with the naked eye and invisible, but could be detected with image enhancement and segmentation might be associated with either one of the proinflammatory cytokines such as IL-2. Aldesleukin is a recombinant form of human interleukin-2, a cytokine that stimulates the proliferation and maturation of T cells, which is used in immune therapy of renal cell cancer and malignant melanoma may occur the facial flushing during or within hours of treatment.¹² The comparison between ICU and non-ICU COVID-19 patients showed that IL-2 and TNF- α were higher in ICU patients than non-ICU-patients.⁴

Facial flushing, a sensitive and specific predictor of dengue infection,¹³ was found in approximately half of the dengue infected patients.¹⁴ Facial flushing was also found in influenza as a physical finding. But none of the clinical features of patients infected with the COVID-19 were reported about the appearance of the facial flushing.^{2, 4, 5}

The decorrelation stretch is a process that is used to enhance (stretch) the color differences found in a color image. It has been used in remote sensing to enhance multispectral images. The National Aeronautics and Space Administration (NASA) has developed a decorrelation stretching method and successfully applied it to enhance the color information of the images and to show up very faint color changes that are almost invisible to the eye. Decorrelation stretching is used to enhance color differences in images with high interchannel correlation.

Therefore, it allows us to see details that are otherwise not so obvious or invisible to the human eye.^{15, 16}

Dunk A., software engineer and Android developer in Australia developed the Rock Art Enhancer app which uses advanced techniques to enhance the colors in photos to make faint features more visible.¹⁷ Techniques used image enhancement such as decorrelation stretching and image segmentation including K-means clustering and color thresholding, but herein, we used color thresholding instead of K-means clustering because it will be more stable and standard in the study. We discovered and detected the subclinical sign in COVID-19 patient that could not be visible and recognized by the naked eye with a novel method using a smartphone application.

Method

We demonstrated the invisible facial flushing in COVID-19 patient rapidly detected by smartphone application. The Rock Art Enhancer app using for Android smartphone in three step technique uses a combination of decorrelation stretching for enhancing the colors in photos to make faint features more visible and with color thresholding for image segmentation as below

Step 1 – Image enhancement: 1st decorrelation stretching the face photos with YUV color space

Step 2 – Image segmentation: color threshold Lab after 1st decorrelation stretching with setting Invert for + and

L : 0 – 255 (L* for the lightness from black to white)

a : 0 - 138 (a* from green to red and setting 138 = +10 from midpoint 128)

b : 0 – 255 (b* from blue to yellow)

Step 3 – Image enhancement: repeating the 2nd decorrelation stretching again with Lab color space.

We applied the Rock Art Enhancer app with the face photo of a COVID-19 patient, a 33-year-old ophthalmologist who was one of the first people to recognize the outbreak of 2019 novel coronavirus disease (COVID-19) in Wuhan, a Chinese doctor who became a folk hero after he was taken in by authorities for warning about the dangers of a deadly new virus now spreading around the world.¹⁸ This innovative technique revealed generalized areas of facial flushing, including on nose, around the eyes, cheeks, and forehead presented in the figure C and D.

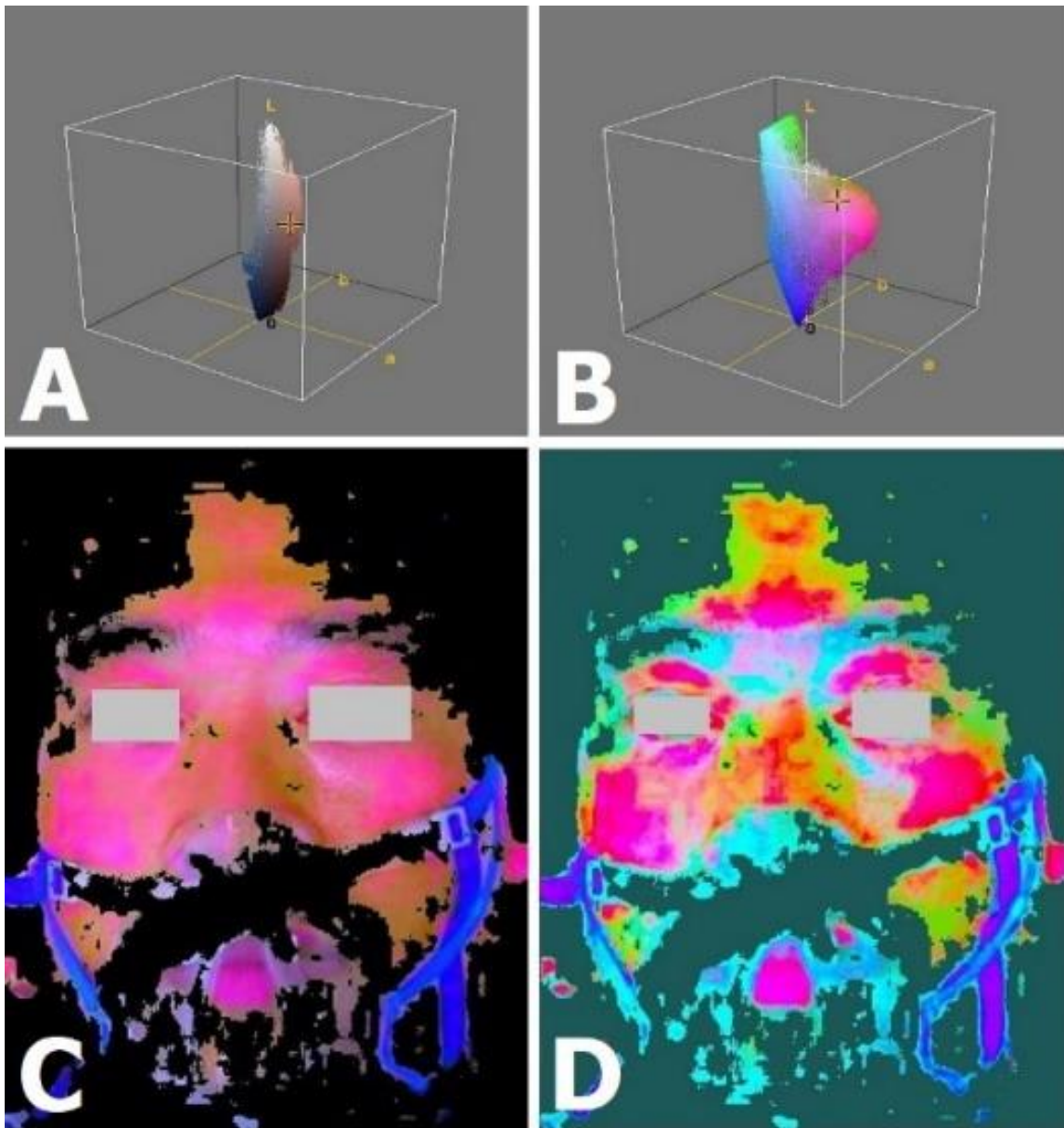


FIGURE. (A) The original face photo revealed invisible facial flushing displayed in the 3D color distribution in the Lab color space using the ImageJ program with the Color Inspector 3D plugin. (B) 1st decorrelation stretching picture using the YUV color space was also displayed in the 3D color distribution in the Lab color space using the ImageJ program with the Color Inspector 3D plugin. Note the exaggerated colors improve visual interpretation and make feature discrimination easier, especially in red color. (C) Color threshold Lab picture after 1st decorrelation stretching. (D) 2nd decorrelation stretching picture using the Lab color space.

If the invisible facial flushing, unrecognized clinical sign with the naked eye could be detected by the smartphone application is the most common clinical features of Coronavirus disease 2019 as seen in dengue infection and influenza, this novel screening tool for diagnosis of COVID-19 patients will help all medical service providers the effective screening tool for the recognition and early diagnosis before performing CT scans and real-time RT PCR (rRT-PCR) assays, especially in some health care facilities where could not be performed due to lack of laboratory support.

Advantages of the detection of the invisible facial flushing in COVID-19 patient by image enhancement and segmentation.

1. Non-contact and non-invasive, only take photos with a smartphone.
2. Available everywhere, almost everyone in every family in the whole country or all levels of medical providers can send the face photos via the internet such as Facebook and Line app.
3. To be useful as a rapid screening tool for diagnosis of COVID-19 before performing CT scans and real-time RT PCR (rRT-PCR) assays.
4. To be useful in active case finding for COVID-19, the key actions to stop transmission for further care and isolation, contact tracing and quarantine.
5. Can be the effective clues for the recognition and early diagnosis of COVID-19.
6. Interpret the findings quickly within 1 minute for three step technique uses a combination of decorrelation stretching with color thresholding for image segmentation.
7. Can be done repeatedly in the next 1-3 days without any pain and more economical than laboratory tests.
8. Can be used in all healthcare facilities in telemedicine following the doctor's advice.

Conclusion

Facial flushing in COVID-19 patient was subclinical sign which was unrecognized and invisible to the naked eye. This is the first case of the COVID-19 patient with the appearance of invisible facial flushing detected by the smartphone application. The process and interpret the finding are rapidly within 1 minute for three step technique. So the enhanced face photos using the

smartphone application may be useful as a rapid screening tool for diagnosis of COVID-19 patients. Furthermore, this clinical discovery with medical image enhancement may apply for all patients with viral induced cytokine storm such as dengue infection, influenza, Ebola, Middle Eastern Respiratory Syndrome coronavirus (MERS-CoV) and Severe acute respiratory syndrome (SARS) caused by SARS coronavirus (SARS-CoV) in the future medicine and may be used in conjunction with thermoscan camera as front line screening and diagnostic capacity.

Conflict of interest

The authors declare that they have no conflict of interest.

Acknowledgments

The authors deeply mourn for all the medical practitioners passing away in the struggle against this emerging infectious disease, COVID-19, especially this patient, as one of the whistle-blowers dedicating his young life in the front line.

References

[1] Dong E, Du H, Gardner L. An interactive web-based dashboard to track COVID-19 in real time. *Lancet Infect Dis*; published online Feb 19. Last updated on April 16, 2020.

[https://doi.org/10.1016/S1473-3099\(20\)30120-1](https://doi.org/10.1016/S1473-3099(20)30120-1).

[2] Guan WJ, Ni ZY, Hu Y, et al. Clinical Characteristics of Coronavirus Disease 2019 in China [published online ahead of print, 2020 Feb 28]. *N Engl J Med*. 2020;10.1056/NEJMoa2002032. doi:10.1056/NEJMoa2002032

[3] Tao Ai, Zhenlu Yang, Hongyan Hou, Chenao Zhan, Chong Chen, Wenzhi Lv, Qian Tao, Ziyong Sun, Liming Xia. Correlation of Chest CT and RT-PCR Testing in Coronavirus Disease 2019 (COVID-19) in China: A Report of 1014 Cases. *Radiology*. Published Online: Feb 26 2020.

<https://doi.org/10.1148/radiol.2020200642>.

[4] Huang C, Wang Y, Li X, et al. Clinical features of patients infected with 2019 novel coronavirus in Wuhan, China [published online ahead of print, 2020

Jan 24] [published correction appears in Lancet. 2020 Jan 30;:]. Lancet. 2020; S0140-6736(20)30183-5. doi:10.1016/S0140-6736(20)30183-5

[5] Wang D, Hu B, Hu C, et al. Clinical Characteristics of 138 Hospitalized Patients With 2019 Novel Coronavirus-Infected Pneumonia in Wuhan, China [published online ahead of print, 2020 Feb 7]. JAMA. 2020;10.1001/jama.2020.1585.

[6] Arpornsuwan M, Arpornsuwan M. Invisible Facial Flushing in Two Cases of Dengue Infection and Influenza detected by PC Program and Smartphone App: Decorrelation Stretching and K-Means Clustering. Case Reports in Infectious Diseases, vol.2020, pp.1-6

<https://doi.org/10.1155/2020/8790130>

[7] Arpornsuwan M, Arpornsuwan M. Application of the Enhanced Single Face Photo as a Novel Screening Tool for Diagnosis of Dengue Infection and Influenza. International Journal of Advance Research, Ideas and Innovation Technology. March-April 2020, vol.6, issue 2, pp.715-724

<https://www.ijariit.com/manuscripts/v6i2/V6I2-1447.pdf>

[8] Tisoncik JR, Korth MJ, Simmons CP, Farrar J, Martin TR, Katze MG. Into the eye of the cytokine storm. Microbiol Mol Biol Rev. 2012;76(1):16–32. doi:10.1128/MMBR.05015-11

[9] Ye Q, Wang B, Mao J. Cytokine Storm in COVID-19 and Treatment [published online ahead of print, 2020 Apr 10]. J Infect. 2020;S0163-4453(20)30165-1. doi:10.1016/j.jinf.2020.03.037

[10] Wong JP, Viswanathan S, Wang M, Sun LQ, Clark GC, D'Elia RV. Current and future developments in the treatment of virus-induced hypercytokinemia. Future Med Chem. 2017;9(2):169–178. doi:10.4155/fmc-2016-0181

<https://www.future-science.com/doi/10.4155/fmc-2016-0181>

[11] Luheshi G, Rothwell N. Cytokines and fever. Int Arch Allergy Immunol. 1996;109(4):301–307. doi:10.1159/000237256

<https://www.karger.com/Article/Abstract/237256>

[12] LiverTox: Clinical and Research Information on Drug-Induced Liver Injury [Internet]. Bethesda (MD): National Institute of Diabetes and Digestive and Kidney Diseases; 2012-. Aldesleukin. [Updated 2018 May 5]. Available from: <https://www.ncbi.nlm.nih.gov/books/NBK548091/>

[13] Parthasarathy A. Textbook of Pediatric Infectious Diseases, JP Medical Ltd., London, UK, 2019.

[14] Sirivichayakul C., Limkittikul K., Chanthavanich P. et al. Dengue infection in children in Ratchaburi, Thailand: a cohort study. II. Clinical manifestations. PLoS Neglected Tropical Disease, vol. 6, no. 2, Article ID e1520, 2012.

DOI:10.1371/journal.pntd.0001520

[15] Alley R. E. Algorithm Theoretical Basis Document for Decorrelation Stretch, Jet Propulsion Laboratory, Pasadena, CA, USA, 1996.

https://eosps0.gsfc.nasa.gov/sites/default/files/atbd/ASTER_ATBD_99-2010.pdf

[16] Harman J. Using decorrelation stretch to enhance rock art images. In Proceedings of American Rock Art Research Association Annual Meeting, Reno, Nevada, May 2005.

<http://www.dstretch.com/AlgorithmDescription.pdf>

[17] Dunk A. Rock Art Enhancer app, BinaryEarth software, Sep 2019.

<https://www.binaryearth.net/RockArtEnhancer/>

[18] Green A. Obituary, Li Wenliang. Lancet 2020, published online Feb 18. [https://doi.org/10.1016/S0140-6736\(20\)30382-2](https://doi.org/10.1016/S0140-6736(20)30382-2)


BIOGRAPHY/BIOGRAPHIES



MANOTE ARPORNSUWAN, M.D.

Manote Arpornsuwan

Clinic Dr.Manote: Buriram 31000, TH
Pediatrician



MATINUN ARPORNSUWAN, M.D.

แม็คตินันท์ อารpornsuwan

Medical Physician, Bangkok 10400, TH